

[To case reports index](#)

Case report

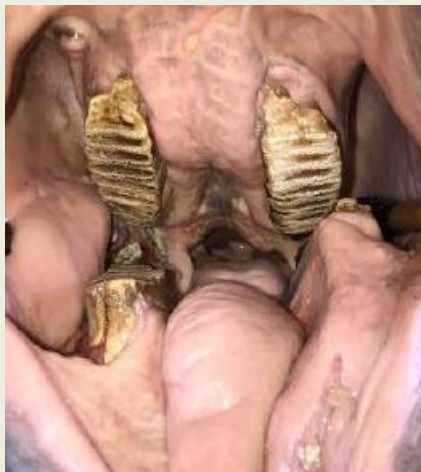Mandibular fracture

Date: 2020

Source: 13th Asian Society of Conservation Medicine Virtual Conference

History

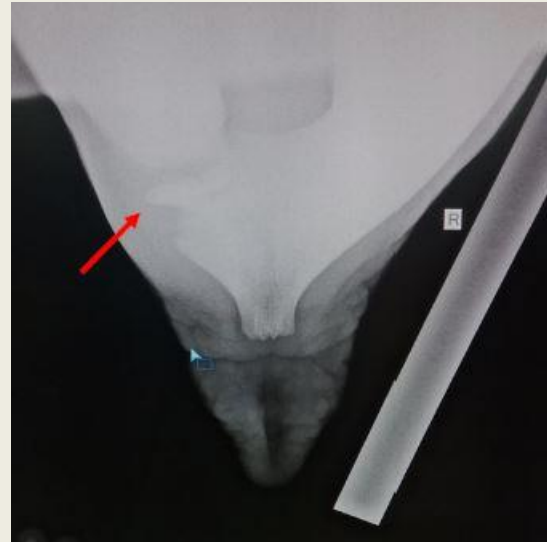
- Coconut-sized abscess on left mandible
- Asymmetric buccal margins
- Tongue ulceration
- Periodontitis
- Endodontitis
- Foul-smelling caseous material
- Malocclusion



Diagnostic results

- Radiography 70kVp, 10mAs
- Lateral and intraoral bisecting angle
- Soft tissue swelling
- Callus formation

Conclusion: Left sided comminuted fracture at the body of the mandible.
Unilateral mandibular fracture on left side
→ Malocclusion → Failure of *M3* extrusion on right side → Impeded eruption of caudal molar on right side → Abnormal eruption of *M5* on right side → Excessive molar abrasion on the left side → Compromised mechanical digestion of food → Anorexia → Malnutrition



Treatment

The animal was not a release candidate, and keeping the animal in captivity for a prolonged period nor permanently was not an option. Therefore, the authorities opted for euthanasia.

[Read the poster](#)

